Copyright EMAP Publishing 2020
This article is not for distribution except for journal club use

Keywords Skin/Hair/Nails/Sweat glands/Sebaceous glands

This article has been double-blind peer reviewed

In this article...

- The four main accessory structures of the skin
- Structure and function of hair and nails
- The role of sweat and sebaceous glands

Skin 2: accessory structures of the skin and their functions

Key points

Accessory structures of the skin include the hair, nails, sweat and sebaceous glands

Hair's primary functions are protection, warmth and sensory reception

Nails protect the tips of the fingers and toes

The two main types of sweat gland – eccrine and apocrine – are responsible for regulating body temperature

Sebaceous glands lubricate and waterproof the skin and hair, and keep them pliable

Author Sandra Lawton is Queen's Nurse, nurse consultant and clinical lead dermatology, The Rotherham NHS Foundation Trust.

Abstract Understanding the skin requires knowledge of its accessory structures. These originate embryologically from the epidermis and include hair, nails, sweat glands and sebaceous glands. All are important in the skin's key functions, including protection, thermoregulation and its sensory roles. This article, the second in a two-part series, looks at the structure and function of the main accessory structures of the skin.

Citation Lawton S (2020) Skin 2: accessory structures of the skin and their functions. *Nursing Times* [online]; 116; 1, 44-46.

Accessory structures of the skin include the hair, nails, sweat glands and sebaceous glands. These structures embryologically originate from the epidermis and are often termed "appendages"; they can extend down through the dermis into the hypodermis (Bit.ly/RUAccessoryStructures).

Hair

The hair is a keratin structure growing out of the epidermis. It is found on all areas of the body except the palms of the hands, soles of the feet and the lips, and has several functions:

- Protection – hair on the head protects the skull from the sun, while that in the nose and ears and around the eyes (eyelashes) traps and excludes dust particles, which may contain allergens and microbes. Eyebrows prevent sweat and other particles from dripping into the eyes;
- Sensory reception – the hair is far more sensitive than the skin surface to air movement or other disturbances in the environment, for example, head-lice infestation;
- Thermoregulation;
- Distribution of sweat-gland products;
- Psychosocial – hair plays an important role in determining self image and social perceptions (Bit.ly/RUAccessoryStructures; Kolarsick et al, 2011; Graham-Brown and Bourke, 2006) .

The hair mainly comprises dead keratinised cells. Strands of hair originate from the hair follicle, which is an epidermal penetration of the dermis. Hair follicles are set at an angle into the dermis, with the bulb (germinal matrix) sitting deep down, just above or in the hypodermis (Graham-Brown and Bourke, 2006). The structure of the dermal papilla (bulb), germinal matrix and root.

The visible hair shaft is the only part that is not anchored to the hair follicle and the shape plays a role in determining hair texture. The rest of the hair (hair root) is anchored in the follicle and lies below the surface of the skin (Fig 1). The hair root ends deep in the dermis at the hair bulb, and includes a layer of mitotically active basal cells called the hair matrix.

Cells of the hair matrix divide and differentiate to form the three layers of the hair:

Copyright EMAP Publishing 2020
This article is not for distribution
except for journal club use

Fig 1. **Anatomy of hair**

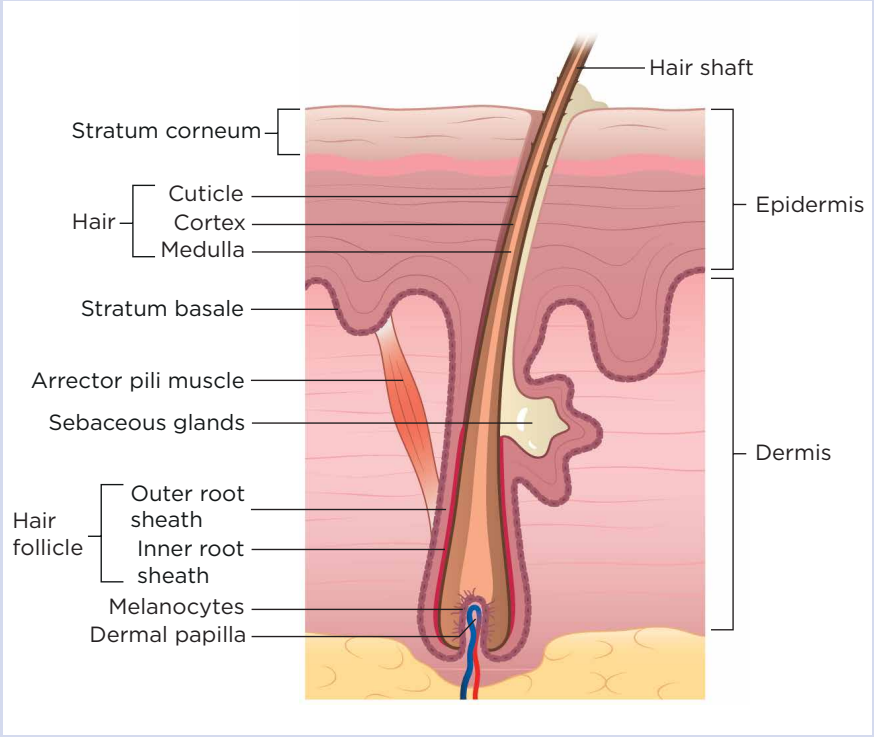

"Hair colour is genetically determined but, as we age, melanin production decreases and the hair loses its colour"

- Medulla – the central core of the hair;
- Cortex – this surrounds the medulla;
- Cuticle – an outer layer of very hard, keratinised cells.

Hair texture is determined by the shape and structure of the cortex and by the shape of the hair follicle:

- Round hair follicle – hair will be straight and coarse;
- Oval hair follicle – hair will be wavy;
- Flat hair follicle – hair will be curly.

The hair bulb surrounds the hair papilla, which is made of connective tissue and contains blood capillaries and nerve endings from the dermis (Bit.ly/RUAccessoryStructures). Also attached to each follicle is a small bundle of smooth muscle, the arrector pili, which contracts with cold, fear and emotion to erect the hairs and produce goosebumps (Gawkrodger and Ardern-Jones, 2016).

There are three types of hair in humans:

- Terminal – scalp, eyebrows/lashes, beard, axillae, pubic areas;
- Vellus – finer downy hair covering the body;
- Lanugo – present in utero and shed before, or at, birth (Gawkrodger and Ardern-Jones, 2016; Graham-Brown and Bourke, 2006).

Hair growth

Hair growth is determined by genetic and hormonal factors, and begins with the production of keratinocytes by the basal cells in the matrix of the hair bulb. Keratinisation is complete when these cells are pushed through the follicle to the skin surface, forming the visible shaft of hair; this shaft is dead and composed entirely of keratin (Bit.ly/RUAccessoryStructures).

Each cycle of hair growth is predetermined and goes through three phases:

- Anagen or growth phase – cells divide rapidly at the hair root, pushing the hair shaft up and out. Hair typically grows at the rate of 0.3mm per day in this phase, which usually lasts from two to seven years;
- Catagen or resting phase – lasting only two or three weeks, this marks a transition from the hair follicle's active growth;
- Telogen or shedding phase – strands of hair are released, no new growth occurs and the follicle is at rest. This lasts for around two to four months before another anagen phase begins. On average
- Fifty hairs are lost and replaced per day (Gawkrodger and Ardern-Jones, 2016; Bit.ly/RUAccessoryStructures; Graham-Brown and Bourke, 2006).

Hair colour

Hair is similar to the skin in that it gets its colour from the pigment melanin, which is produced by melanocytes in the hair papilla. Hair colour is genetically determined but, as we age, melanin production decreases and the hair loses its colour, becoming grey and/or white.

Sebaceous glands

The pilosebaceous unit comprises the hair follicle, hair shaft, arrector pili and sebaceous glands. The sebaceous glands are found along the hair follicles and secrete a liquid substance called sebum (a mix of lipids) in response to hormonal stimulation. The glands vary in size and number, but are mostly on the scalp, face, upper torso and anogenital areas. They are relatively inactive during childhood, but become very active during puberty.

Fig 2. **Eccrine and apocrine sweat glands**

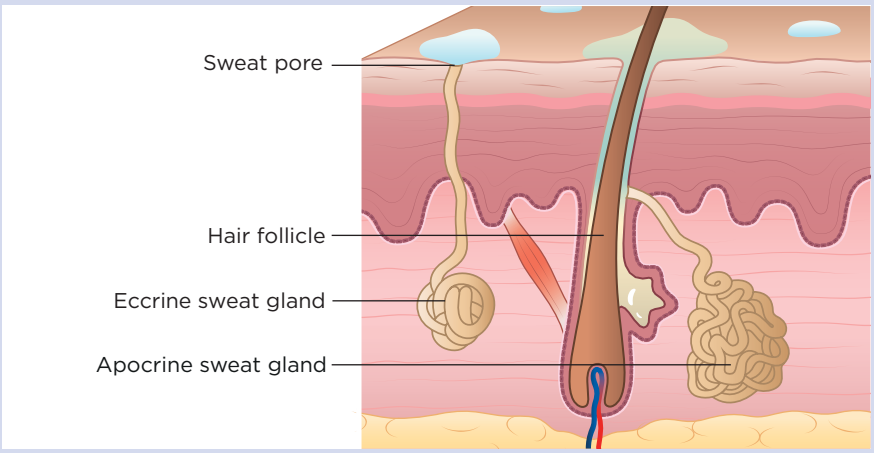

FRANCESCA CORRA

Copyright EMAP Publishing 2020
This article is not for distribution
except for journal club use

Fig 3. **Structure of the nail**

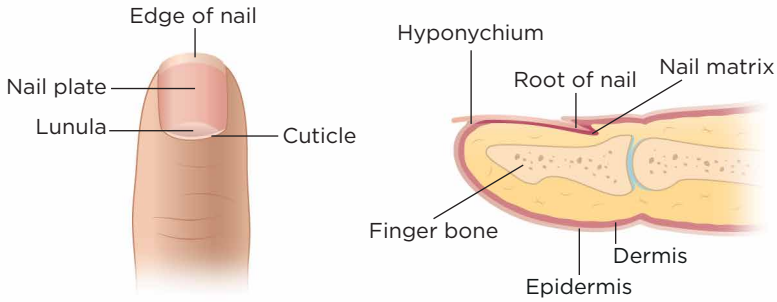

Sebum helps lubricate and waterproof the skin and hair, keeping them pliable; the fatty acids of sebum also have antibacterial properties and prevent water loss from the skin in low-humidity environments (Bit.ly/RUAccessoryStructures).

Sweat glands

Also known as sudoriferous glands (from the Latin *sudor*, meaning sweat), these produce sweat to cool the body when it becomes warm. Sweat glands develop from epidermal projections into the dermis and are classified as eccrine glands, as the secretions are excreted by exocytosis through a duct without affecting the cells of the gland. There are two types of sweat glands – eccrine and apocrine – each of which secretes slightly different products (Bit.ly/RUAccessoryStructures).

Eccrine sweat glands

Eccrine sweat glands are part of the body's thermoregulatory system and help to maintain homeostasis. There are more than two million of these and, although they are found over the whole body, they are more numerous in the forehead, axillae, palms of the hands and soles of the feet. These coiled structures are usually at the junction between the dermis and the subcutaneous layer, with a duct leading through the dermis and epidermis to a pore on the skin surface, where the sweat is released (Graham-Brown and Bourke, 2006; Fig 2).

The sweat, released by exocytosis, is hypotonic and mostly water, with some salt, antibodies, traces of metabolic waste and dermcidin, an antimicrobial peptide.

Apocrine sweat glands

Apocrine sweat glands become active during puberty, and are also coiled structures; their ducts open into hair follicles (Fig 2). They are larger than eccrine sweat glands, lie deeper in the dermis and are sometimes found in the hypodermis. Less numerous than eccrine glands, they are found in the axillae as well as in more-localised sites – namely the nipples, perineum and scalp.

> *"Apocrine sweat includes organic compounds that make the sweat thicker than eccrine sweat and subject to bacterial decomposition and subsequent smell"*

Apocrine sweat, as well as containing water and salts, includes organic compounds that make it thicker than eccrine sweat and subject to bacterial decomposition and subsequent smell. The release of this sweat is under nervous and hormonal control. Apocrine sweat plays a role in the poorly understood human pheromone response and regulating body temperature (Bit.ly/RUAccessoryStructures; Graham-Brown and Bourke, 2006).

Nails

Nails consist of hardened and densely packed keratin, and protect the extremities of our fingers and toes from mechanical damage. Offering protection for the fingertips, they facilitate grasping and tactile sensitivity in the finger. The fingertip has many nerve endings and receives information about objects we touch; the nail acts as a counterforce, providing even more sensory input.

The components making up the structure of the nail are shown in Fig 3 and described below:

- Nail matrix – the growing part of the nail, still under the skin at the nail's proximal end, containing cells that divide, mature, keratinise and move forward to the nail plate;
- Nail plate – this hard and translucent portion is composed of keratin, and varies in thickness from 0.3mm to 0.5mm ;
- Cuticle (eponychium) – the cuticle is the fold of skin at the proximal end of the nail;
- Paronychium – the lateral fold of skin on the sides of the nail;
- Nail bed – this is adherent connective tissue underlying the nail; it is rich in blood vessels, making it appear pink, except at the base, where a thick layer of epithelium over the nail matrix forms a crescent-shaped region called the lunula ("little moon");
- Hyponychium – the area beneath the free edge of the nail, farthest from the cuticle; it consists of a thickened layer of stratum corneum (Bit.ly/RUAccessoryStructures; Gawkrodger and Ardern-Jones, 2016).

Nail growth

The rate of nail growth varies from person to person: fingernails average between 0.5mm and 1.2mm per week, but toenails grow more slowly (Weller et al, 2013). The growth of nails is a complex process and, in humans, is genetically controlled to ensure the nail is flat; this is unlike the process in other animals and primates that have claws. Nail growth can also be negatively affected by trauma and inflammation (Graham-Brown and Bourke, 2006).

Conclusion

The accessory structures of the skin, including the hair, nails, sweat glands and sebaceous glands, play an important role in the skin's key functions. **NT**

References

Gawkrodger DJ, Ardern-Jones M (2016) *Dermatology: An Illustrated Colour Text.* London: Elsevier.

Graham-Brown R, Bourke J (2006) *Mosby's Colour Atlas and Text of Dermatology.* London: Mosby Elsevier.

Kolarsick PAJ et al (2011) Anatomy and physiology of the skin. *Journal of the Dermatology Nurses' Association;* 3: 4, 203-213.

Weller RB et al (2013) *Clinical Dermatology.* Oxford: Blackwell Science.

CLINICAL SERIES **Skin series**

Part 1:	Structure and functions of the skin **Bit.ly/NTTheSkin1**	Dec 2019
Part 2:	Accessory structures of the skin and their functions	Jan 2020

FRANCESCA CORRA